

# Retrospective Case Series Analysis of a Nasal Expiratory Positive Airway Pressure (EPAP) Device to Treat Obstructive Sleep Apnea in a Clinical Practice

Glenn Adams, MD, FCCP<sup>1,2,3</sup>

<sup>1</sup>Sleep, Pulmonary, Critical Care Medicine, Sleep Medicine Specialists, PLLC, Sarasota, FL, United States.

<sup>2</sup>Medical Director, Sleep Disorders Center, Sarasota Memorial Hospital, Sarasota, FL, United States.

<sup>3</sup>Clinical Assistant Professor, Florida State University Medical School, Sarasota, FL, United States.

## Introduction

Continuous positive airway pressure (CPAP) is considered the gold standard treatment for patients with obstructive sleep apnea (OSA). However, other treatment alternatives for OSA are needed to provide increased compliance and additional choices for patients and prescribing physicians. Prior studies<sup>1-5</sup> have reported that a nasal expiratory positive airway pressure (EPAP) device (PROVENT® Therapy, Ventus Medical, Inc) significantly reduced the apnea-hypopnea index (AHI) as well as improved oxygenation and subjective daytime sleepiness. This retrospective analysis was conducted to evaluate real-world patient acceptance and outcomes of this new therapeutic option in a clinical setting.

## Methods

Patients with a diagnosis of obstructive sleep apnea (AHI > 10/hour or AHI >5 with excessive sleepiness and well recognized co-morbidities) were approached to try nasal EPAP. 97% of the patients were either CPAP failures or current CPAP users. Patients received 10 nights of sample devices for in-home acclimation evaluation. Patients that acclimated were asked to return for efficacy confirmation using standard in-lab polysomnography (PSG). During the PSGs, adjunctive therapy (e.g. chin straps, positional therapy) was used, when necessary, to achieve optimal efficacy. Patients with demonstrated efficacy were given a prescription for nasal EPAP.

## Results

At a single center, 151 patients sampled nasal EPAP and 131 are in the analysis group (16 patients pending follow up and 4 status unknown). Of the analysis group, 98 patients (75%) acclimated to the device. The overall median AHI was reduced from 25.8 to 4.2 ( $p < 0.001$ ) [Figure 1]. In patients with severe OSA, the median AHI was reduced from 48.7 to 5.6 (Figure 2). Effectiveness (AHI < 10) was achieved in 80.7% of all patients and 90.6% of mild/moderate OSA patients (Figure 3). AHI was reduced to less than 5 in 56.3% of patients (63.9% of mild/moderate OSA patients) (Figure 3). When EPAP was used in combination with chin straps and/or positional therapy, median AHI was reduced to <6 in all 3 concomitant therapy subgroups (Figure 4).

## Summary and Conclusions

The nasal EPAP device provided a statistically significant and clinically meaningful reduction in AHI in a group of clinical practice patients with mild, moderate and severe OSA as follows:

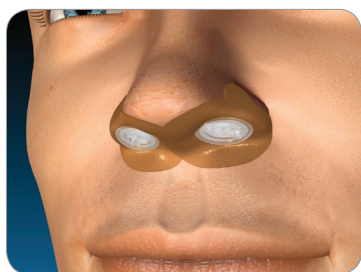
AHI	Baseline	Nasal EPAP
All Patients	25.8	4.2
Mild OSA	11.5	3.4
Moderate OSA	23.9	4.2
Severe OSA	48.7	5.6

EPAP therapy was accepted by 75% of the patients. Use of a chin strap and/or positional therapy in combination with EPAP may contribute to higher effectiveness rates as compared to currently published results. Standard in-lab polysomnography is recommended for effectiveness confirmation in order to evaluate the impact of concomitant therapy.

## References

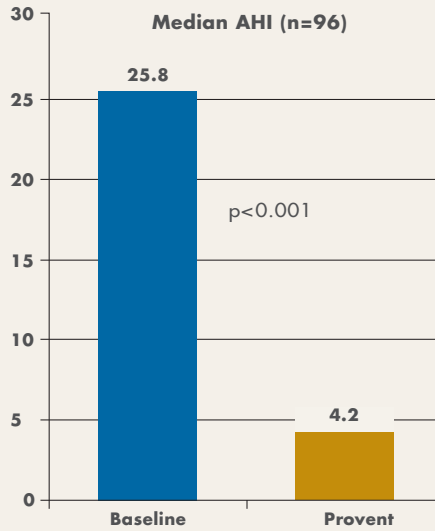
1. Colrain IM, Brooks S, Black J. J Clin Sleep Med 2008;4:426-33.
2. Rosenthal L, Massie CA, Dolan DC, Loomas B, Kram J, Hart RW. J Clin Sleep Med. 2009;5:532-7.
3. Walsh JK, Griffin KS, Forst EH, Ahmed HH, Eisenstein RD, Curry DT, Hall-Porter JM, Schweitzer PK. Sleep Med. 2011;12:147-52.
4. Patel AV, Hwang D, Masdeu MJ, Chen GM, Rapoport DM, Ayappa I. J Clin Sleep Med. 2011 7:13-22.
5. Berry RB, Kryger MH, Massie CA. Sleep. 2011;34:479-85.

## Provent® Sleep Apnea Therapy

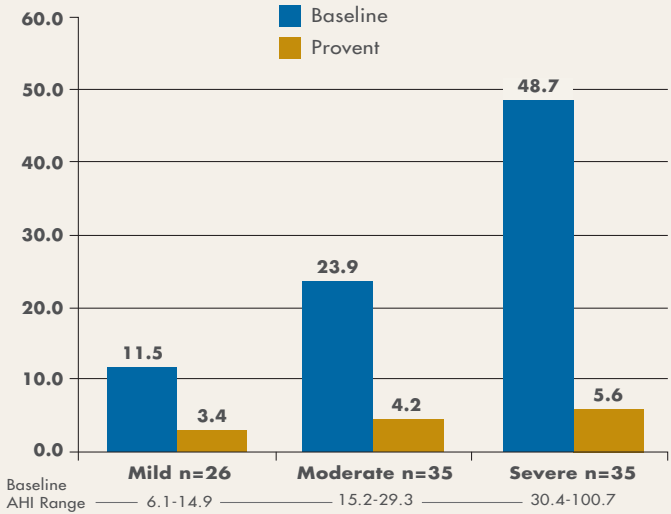


Actual Size

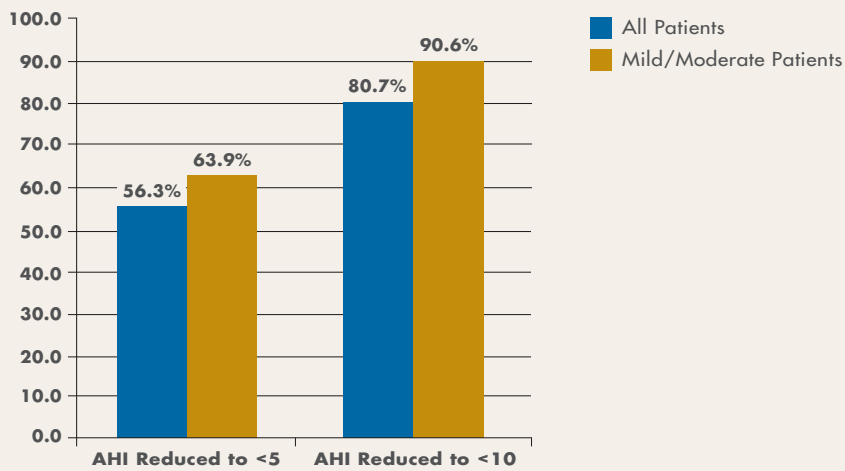
**Figure 1.** Median AHI Baseline vs Nasal EPAP (Provent)



**Figure 2.** Median AHI by OSA Severity



**Figure 3.** Successfully Treated Patients, AHI <5 and <10



**Figure 4.** AHI Improvement in Concomitant Therapy Subgroups

